

# World Journal of *Stem Cells*

*World J Stem Cells* 2022 October 26; 14(10): 744-790



**MINIREVIEWS**

- 744 Therapeutic applications of adipose-derived stromal vascular fractions in osteoarthritis

*Tang Q, Zhao XS, Guo A, Cui RT, Song HL, Qi ZY, Pan Y, Yang Y, Zhang FF, Jin L*

**ORIGINAL ARTICLE****Basic Study**

- 756 Maternal inappropriate calcium intake aggravates dietary-induced obesity in male offspring by affecting the differentiation potential of mesenchymal stem cells

*Li P, Wang Y, Li P, Liu YL, Liu WJ, Chen XY, Tang TT, Qi KM, Zhang Y*

- 777 Exosomes from circ-Astn1-modified adipose-derived mesenchymal stem cells enhance wound healing through miR-138-5p/SIRT1/FOXO1 axis regulation

*Wang Z, Feng C, Liu H, Meng T, Huang WQ, Song KX, Wang YB*

**ABOUT COVER**

Editorial Board Member of *World Journal of Stem Cells*, Venera Cardile, PhD, Associate Professor, Department of Biomedical and Biotechnological Sciences, BIOMETEC, Section of Physiology, University of Catania, Via Santa Sofia 97, Catania 95123, Italy. cardile@unict.it

**AIMS AND SCOPE**

The primary aim of *World Journal of Stem Cells (WJSC, World J Stem Cells)* is to provide scholars and readers from various fields of stem cells with a platform to publish high-quality basic and clinical research articles and communicate their research findings online. *WJSC* publishes articles reporting research results obtained in the field of stem cell biology and regenerative medicine, related to the wide range of stem cells including embryonic stem cells, germline stem cells, tissue-specific stem cells, adult stem cells, mesenchymal stromal cells, induced pluripotent stem cells, embryonal carcinoma stem cells, hemangioblasts, lymphoid progenitor cells, etc.

**INDEXING/ABSTRACTING**

The *WJSC* is now abstracted and indexed in Science Citation Index Expanded (SCIE, also known as SciSearch®), Journal Citation Reports/Science Edition, PubMed, PubMed Central, Scopus, Biological Abstracts, BIOSIS Previews, Reference Citation Analysis, China National Knowledge Infrastructure, China Science and Technology Journal Database, and Superstar Journals Database. The 2022 Edition of Journal Citation Reports cites the 2021 impact factor (IF) for *WJSC* as 5.247; IF without journal self cites: 5.028; 5-year IF: 4.964; Journal Citation Indicator: 0.56; Ranking: 12 among 29 journals in cell and tissue engineering; Quartile category: Q2; Ranking: 86 among 194 journals in cell biology; and Quartile category: Q2. The *WJSC*'s CiteScore for 2021 is 5.1 and Scopus CiteScore rank 2021: Histology is 17/61; Genetics is 145/335; Genetics (clinical) is 42/86; Molecular Biology is 221/386; Cell Biology is 164/274.

**RESPONSIBLE EDITORS FOR THIS ISSUE**

Production Editor: Xiang-Di Zhang; Production Department Director: Xu Guo; Editorial Office Director: Jia-Ru Fan.

**NAME OF JOURNAL**

*World Journal of Stem Cells*

**ISSN**

ISSN 1948-0210 (online)

**LAUNCH DATE**

December 31, 2009

**FREQUENCY**

Monthly

**EDITORS-IN-CHIEF**

Shengwen Calvin Li, Carlo Ventura

**EDITORIAL BOARD MEMBERS**

<https://www.wjgnet.com/1948-0210/editorialboard.htm>

**PUBLICATION DATE**

October 26, 2022

**COPYRIGHT**

© 2022 Baishideng Publishing Group Inc

**INSTRUCTIONS TO AUTHORS**

<https://www.wjgnet.com/bpg/gerinfo/204>

**GUIDELINES FOR ETHICS DOCUMENTS**

<https://www.wjgnet.com/bpg/GerInfo/287>

**GUIDELINES FOR NON-NATIVE SPEAKERS OF ENGLISH**

<https://www.wjgnet.com/bpg/gerinfo/240>

**PUBLICATION ETHICS**

<https://www.wjgnet.com/bpg/GerInfo/288>

**PUBLICATION MISCONDUCT**

<https://www.wjgnet.com/bpg/gerinfo/208>

**ARTICLE PROCESSING CHARGE**

<https://www.wjgnet.com/bpg/gerinfo/242>

**STEPS FOR SUBMITTING MANUSCRIPTS**

<https://www.wjgnet.com/bpg/GerInfo/239>

**ONLINE SUBMISSION**

<https://www.f6publishing.com>



## Therapeutic applications of adipose-derived stromal vascular fractions in osteoarthritis

Qi Tang, Xian-Sheng Zhao, Ao Guo, Ruo-Tong Cui, Huai-Le Song, Zi-Yang Qi, Yi Pan, Yue Yang, Fang-Fang Zhang, Liang Jin

**Specialty type:** Cell biology

**Provenance and peer review:**

Unsolicited article; Externally peer reviewed.

**Peer-review model:** Single blind

**Peer-review report's scientific quality classification**

Grade A (Excellent): 0  
Grade B (Very good): B, B  
Grade C (Good): C, C  
Grade D (Fair): D, D  
Grade E (Poor): 0

**P-Reviewer:** Georgiev T, Bulgaria; Jennane R, France; Konrads C, Germany; Moretti A, Italy; Muthu S, India

**Received:** April 6, 2022

**Peer-review started:** April 6, 2022

**First decision:** June 22, 2022

**Revised:** July 8, 2022

**Accepted:** September 12, 2022

**Article in press:** September 12, 2022

**Published online:** October 26, 2022



Qi Tang, Ao Guo, Ruo-Tong Cui, Huai-Le Song, Zi-Yang Qi, Yi Pan, Yue Yang, Fang-Fang Zhang, Liang Jin, School of Life Science and Technology, China Pharmaceutical University, Nanjing 211198, Jiangsu Province, China

Xian-Sheng Zhao, Department of Dermatology, Huashan Hospital, Fudan University, Shanghai 200040, China

**Corresponding author:** Liang Jin, PhD, Professor, School of Life Science and Technology, China Pharmaceutical University, No. 24 Tongji Xiang Avenue, Nanjing 211198, Jiangsu Province, China. [ljstemcell@cpu.edu.cn](mailto:ljstemcell@cpu.edu.cn)

### Abstract

Osteoarthritis (OA) is considered to be a highly heterogeneous disease with progressive cartilage loss, subchondral bone remodeling, and low-grade inflammation. It is one of the world's leading causes of disability. Most conventional clinical treatments for OA are palliative drugs, which cannot fundamentally cure this disease. The stromal vascular fraction (SVF) from adipose tissues is a heterogeneous cell population. According to previous studies, it contains a large number of mesenchymal stem cells, which have been used to treat OA with good therapeutic results. This safe, simple, and effective therapy is expected to be applied and promoted in the future. In this paper, the detailed pathogenesis, diagnosis, and current clinical treatments for OA are introduced. Then, clinical studies and the therapeutic mechanism of SVF for the treatment of OA are summarized.

**Key Words:** Arthritis; Articular cartilage; Stromal vascular fraction; Mesenchymal stem cells; Cell therapy

©The Author(s) 2022. Published by Baishideng Publishing Group Inc. All rights reserved.

**Core Tip:** Osteoarthritis (OA) is one of the world's leading causes of disability. Clinically, palliative drugs cannot fundamentally cure this disease. The stromal vascular fraction (SVF) from adipose tissues is a heterogeneous cell population. According to studies, it contains a large number of mesenchymal stem cells, which have been used to treat OA with good therapeutic effects. In this review, we present an updated status of the comprehensive and systematic review of pathogenesis, diagnosis, and current clinical treatments for OA, especially focusing on therapeutic applications of adipose-derived SVF.

**Citation:** Tang Q, Zhao XS, Guo A, Cui RT, Song HL, Qi ZY, Pan Y, Yang Y, Zhang FF, Jin L. Therapeutic applications of adipose-derived stromal vascular fractions in osteoarthritis. *World J Stem Cells* 2022; 14(10): 744-755

**URL:** <https://www.wjgnet.com/1948-0210/full/v14/i10/744.htm>

**DOI:** <https://dx.doi.org/10.4252/wjsc.v14.i10.744>

## INTRODUCTION

Osteoarthritis (OA) was once thought to be a degenerative joint disease, but recent research has revealed that cartilage, subchondral bone, and synovium in the joints can all develop and form varying degrees of inflammation. As a result, OA is considered a whole joint disease. It is marked by an imbalance in the catabolic and anabolic processes of articular cartilage, as well as compensatory changes in bone and synovial inflammation, all of which ultimately lead to joint dysfunction[1,2].

The major feature of OA is the degeneration of articular cartilage and subchondral bone, which eventually results in joint swelling, pain, stiffness, limited mobility, effusion and inflammation, and even disability. This disease not only causes patients to experience considerable pain but also places a great economic burden on them and on society. Aging, genetic susceptibility, obesity, high bone mineral density (BMD), joint overuse, and injury are among the main causes of OA, according to researchers[3].

The Global Burden of Disease study for 2017 was published in The Lancet in 2018, and Safiri used it to conduct a systematic analysis of OA. From 1990 to 2017, the global age-standardized point prevalence, annual incidence, and years lived with disability rates of OA increased by 9.3% (95% UI: 8%-10.7%), 8.2% (95% UI: 7.1%-9.4%), and 9.6% (95% UI: 8.3%-11.1%), respectively. It is worth noting that the prevalence of OA in females was higher than that in males. Furthermore, both the morbidity and prevalence of OA rise with age, with the prevalence of cases peaking at 60-64 years old[4].

Obesity, in addition to age, is a significant risk factor for OA. Obesity puts more strain on weight-bearing joints. At the same time, adipocytes may also play a role in the pathogenesis of OA by secreting inflammatory factors. These factors increase the production of matrix metalloproteinases (MMPs) and prostaglandins while inhibiting the synthesis of proteoglycans and type II collagen, affecting cartilage function[5]. Obese patients (BMI > 30 kg/m<sup>2</sup>) are more likely to need total knee arthroplasty and have higher rates of postoperative complications, according to studies[6].

Genetic factors account for 30%-65% of OA cases. A genome-wide association scanning study has identified 21 independent OA susceptibility loci[7]. Articular cartilage injury, anterior cruciate ligament (ACL) rupture, and meniscus tear (MT) all greatly increase the risk of OA. According to one study, people who have had knee injuries are four times more likely to develop OA than those who have not had knee injuries[8]. In addition, a low vitamin D diet[9] and excessive joint use[10] may also increase the risk of OA. High BMD increases the risk of knee OA and joint space narrowing, but does not worsen the imaging progression of existing knee OA, according to one study[11].

Since OA can cause great personal and economic losses, we must pay attention to it. The purpose of this paper is to introduce the pathogenesis, diagnosis and current clinical treatment methods of OA and briefly summarize the clinical researches and mechanisms of SVF in the treatment of osteoarthritis.

## PATHOGENESIS OF OA

Cartilage destruction, subchondral bone remodeling, osteophyte formation, and joint capsule thickening are all parts of the pathogenesis of OA, which may take several years. It should be noted that prearthritic deformities of the limbs could also lead to osteoarthritis. For example, severe valgus or varus malalignment leads to lateral or medial gonarthrosis. This can produce a change in the distribution of high stresses within the joint, resulting in a force imbalance, which in turn accelerates arthritic pathology[12]. The inflammation of OA is low-grade and chronic, causing both the innate and adaptive immune systems to be activated (primarily the innate immune system), distinguishing OA from rheumatoid arthritis[13].

Normally, articular cartilage consists of water, chondrocytes, and extracellular matrices. The extracellular matrix is synthesized and secreted by chondrocytes and contains collagen (mainly type II collagen), proteoglycans, hyaluronic acid (HA), and small-molecule glycoproteins. Type II collagen and other extracellular matrices can form a reticular structure, which provides pressure resistance for articular cartilage[14]. When OA occurs, chondrocytes produce a variety of inflammatory cytokines and chemokines that cause inflammation, such as interleukin-1 $\beta$  (IL-1 $\beta$ ), tumor necrosis factor- $\alpha$  (TNF- $\alpha$ ), and interleukin-6 (IL-6). Concurrently, chondrocytes produce MMPs, as well as disintegrin and metalloproteinase with thrombospondin-like motifs (ADAMTS). Type II collagen is the target of disintegrin, and proteoglycans are the targets of ADAMTS; together, these proteins eventually lead to increased cartilage catabolism and reduced synthetic metabolism and repair[15]. It is worth noting that osteoblasts, synovial cells, and monocytes in joints can produce IL-1 $\beta$ , TNF- $\alpha$ , MMPs, *etc*[15].

Subchondral bone, which is located beneath the calcified layer of articular cartilage and contains blood vessels and nerves, may provide mechanical support for articular cartilage. In the early stage of OA, osteoclasts mediate the remodeling of subchondral bones. Magnetic resonance imaging (MRI) can detect various degrees of subchondral bone sclerosis, osteophytes, and subchondral bone cysts as OA progresses[16,17]. This modification may reduce the mechanical support provided by subchondral bones to articular cartilage, making the articular cartilage vulnerable to damage.

Synovitis is one of the most common complications of OA. The synovium may proliferate significantly during the progression of OA, and synovial cells may also secrete proinflammatory factors and MMPs to aid in the development of OA[18]. In addition to the local inflammatory mechanism of joints, increasing evidence suggests that obesity can keep the human body in a low-degree inflammatory environment for an extended period of time. Obese people have a significantly higher risk of OA than people with a normal BMI[6].

## DIAGNOSIS AND THERAPY OF OA

The primary method of diagnosing OA is imaging examination, which mainly includes X-rays, computed tomography (CT), MRI, ultrasonography, and arthroscopy. X-ray examination is one of the preferred methods for the clinical diagnosis of OA[19,20]. It can detect key features of OA, such as joint space narrowing, osteophytes, subchondral bone sclerosis, and cysts. However, because X-ray images can only visualize cartilage damage indirectly by observing changes in joint spaces and bones, it cannot be used as the sole criterion for OA diagnosis, and it is not suitable for OA diagnosis in the early stages [21]. CT scan can reveal subtle bone changes in the subchondral bone. The images can clearly show the loose bodies formed by osteophyte shedding around the joints on different sides. As a result, it is more sensitive for detecting osteophytes and subchondral cysts[22]. Because MRI has higher tissue resolution, it can provide information about the size and structural integrity of cartilage, as well as directly show articular cartilage damage and changes in thickness[23]. Furthermore, because MRI can detect OA-inducing factors such as injuries to the ACL and meniscus, it is useful for detecting OA at an early stage [23]. Although ultrasonography can detect joint exudation and inflammation, it cannot diagnose deeper joints as well as MRI[24]. Arthroscopy is the use of an arthroscope to penetrate deep into the joint cavity and directly observe tissues such as the articular cartilage and meniscus. It can not only pinpoint the location of synovitis but can also clean up the joints by removing loose bodies, removing torn meniscus tissue, and trimming bone surfaces. This diagnostic method can both diagnose and treat OA, making it the most promising diagnostic tool for assessing joint damage[25]. When features of OA appear on images in the clinic, it usually means that the patient has irreversible cartilage damage.

Biomarkers have won a place in the diagnosis of OA because they can be used as indicators for its early diagnosis and prognosis. Biomarkers of OA are distributed in the blood, urine, and joint fluid and primarily consist of cytokines related to joint metabolism, extracellular matrix components, inflammatory factors, *etc*. Currently, commonly used indicators are cartilage oligomeric matrix protein, HA, proteoglycan, MMP, C-telopeptide of type II collagen (CTX-II), IL-6, and lactate dehydrogenase[26]. Although biomarkers can be used to make an early diagnosis of OA, their sensitivity and specificity are not satisfactory[27]. Because each of the methods listed above has advantages and disadvantages, it is necessary to combine them to provide comprehensive and reliable information for the diagnosis of OA, as well as a scientific reference for developing an OA treatment plan.

Treatment for OA primarily consists of lifestyle changes, physical therapy, drug therapy, intra-articular therapy, and surgery. However, there is no complete cure for OA. The goal of treatment in the early stage of OA is to reduce pain and stiffness. Therapeutic approaches normally involve moderate exercise, diet, and oral medication. The goal of treatment in the intermediate and late stages of OA is to maintain physical function. The therapeutic approaches normally include intraarticular injection therapy and surgery. According to the Osteoarthritis Research Society International, suitable structured land-based exercise is one of the most effective ways to treat OA, as it can reduce joint pain and stiffness. Furthermore, losing weight is also one of the important ways for obese patients to improve OA [28]. Physical therapy includes electrotherapy, thermotherapy, and acupuncture. Analgesic, anti-inflammatory, and cartilage-protecting drugs are commonly used in drug therapy. However, these therapies



can only alleviate pain symptoms and slow the inflammatory process; they cannot prevent the development of OA. In clinical practice, articular cavity injection therapy is a minimally invasive treatment method. The injected treatment agents include glucocorticoids, sodium hyaluronate, platelet-rich plasma (PRP), bone morphogenetic protein 7 (BMP-7), and stem cells. It should be noted that ultrasound can be used to guide the use of intraarticular injections in patients with advanced osteoarthritis and obesity. A novel intraarticular injectable drug-loaded delivery system using nanoscale materials, including micelles, liposomes, and dendrimers, has been proposed. This method can slow drug release and prolong drug retention time in the joint cavity[29]. The surgical therapies for OA treatment mainly include arthroscopic debridement, microfracture, allogeneic/autologous cartilage transplantation, and artificial joint replacement. For example, for frontal malalignment and varus or valgus malalignment, high tibial osteotomy could be used to correct the proximal tibial angle, thereby reducing pain and delaying the progression of arthritis[30]. However, surgery is invasive and comes with certain risks. Therefore, it is only applicable for patients who have severe degenerative changes in their joints, such as reduced or eliminated joint space, which severely impairs their quality of life[31]. This therapy is not appropriate for the treatment of early-stage OA.

## STROMAL VASCULAR FRACTION

SVF is a multicellular component extracted from adipose tissues through a process that includes collagenase digestion, centrifugation, washing, and filtration. Clinically, liposuction, for example, can be used to obtain adipose tissues from areas such as the abdomen, groin, forearm, and hip. Methods currently used to extract SVF mainly include enzyme digestion and mechanical separation. Because the cell yield obtained by enzyme digestion is higher than that obtained by mechanical separation, researchers prefer enzyme digestion[32-34]. However, if the final product of the enzyme digestion method is not completely washed, it may retain exogenous collagenase, so it is subject to strict regulatory standards in use.

The cell components of SVF could be identified by cell surface molecules such as the cluster of differentiation (CD)[35]. According to the International Federation for Adipose Therapeutics and Science and the International Society for Cellular Therapy, SVF is primarily composed of adipose mesenchymal stem cells (ADSCs), hematopoietic stem/progenitor cells, lymphocytes, monocytes/macrophages, endothelial cells, and pericytes[36]. According to research, CD45-CD235a-CD31-CD34+ is a marker combination to identify SVF cells. ADSCs are a critical component of SVF, accounting for approximately 10% of the SVF cell population[37]. ADSCs endow SVF with characteristics of stem cells, and other cells also play a positive role in secreting active cytokines and regulating body immunity. Because SVF has demonstrated excellent therapeutic value in tissue regeneration, vascular reconstruction, and anti-inflammatory properties, it is widely used in clinical practice.

The keywords "stromal vascular fraction" and "osteoarthritis" were used to search the clinical research database (<https://www.clinicaltrials.gov/>). After the withdrawn studies were removed, the current clinical trial studies of SVF in the treatment of osteoarthritis were obtained, as shown in Table 1.

## CLINICAL RESEARCHES OF SVF IN OA

Clinically, drug therapy for OA can relieve pain and some symptoms, but it cannot repair or inhibit the damage to cartilage and other joint tissues. As a result, it can neither fundamentally solve the problem of cartilage degeneration nor prevent the progression of OA. Although surgical therapy may be used to repair cartilage damage, the long-term treatment effect of OA is limited, and there are numerous drawbacks and risks. Additionally, it should be noted that surgical treatment is only suitable for the treatment of patients with OA in the middle and late stages. Therefore, the minimally invasive, safe, and rapid therapy of stem cell injection into the joint cavity has gained more attention and use.

Mesenchymal stem cells (MSCs) are derived from the mesoderm and can differentiate into adipocytes, osteoblasts, chondrocytes, and other mesoderm cells[38]. This differentiation potential makes MSCs a promising alternative treatment for OA. MSCs can be derived from the umbilical cord, bone marrow, and adipose tissue. When compared to other source tissues, adipose tissues are rich in content, easier to obtain (through liposuction), and contain more stem cells (ADSCs)[39]. ADSCs are a type of MSC. Furthermore, ADSCs have higher genetic stability, a higher ability for proliferation and differentiation, a lower rate of aging, and longer telomere length[40], making them the most promising treatment option for OA.

ADSCs can be obtained by SVF after *in vitro* adherence culture and amplification. However, because the cumbersome and time-consuming *in vitro* amplification step poses a contamination risk, as well as time and economic costs, the researchers shifted their focus to SVF, which does not require culture. The rich cellular components in SVF can not only differentiate into chondrocytes to aid in tissue repair but also secrete active cytokines and regulate the body's immune system to exert anti-inflammatory effects, among other things. As a result, clinical researchers prefer SVF.

**Table 1 Clinical trials of stromal vascular fraction in the treatment of osteoarthritis**

Main conditions	NCT number	Phase
Osteoarthritis	NCT03818737	Phase III
Osteoarthritis	NCT02846675, NCT02967874	Phase II
Knee osteoarthritis	NCT04050111	Phase II
Knee osteoarthritis	NCT02276833, NCT04043819, NCT03940950	Phase I
		Phase I
Osteoarthritis	NCT03166410, NCT02697682, NCT02726945	Preclinical
		Preclinical
Knee osteoarthritis	NCT04440189, NCT02726945, NCT04440189	Preclinical
		Preclinical

NCT: National Clinical Trial.

This study used the keywords "stromal vascular fraction" and "osteoarthritis" to search PubMed, Web of Science, Cochrane Library, and Google Scholar, and after removing duplicates and non-English literature, we screened clinical trials of SVF treatment for OA published between 2016 and 2020. Finally, 22 studies were obtained, as shown in Table 2[41-62].

The majority of the studies in Table 2 are for knee OA, and approximately half of the clinical studies are uncontrolled and without combination therapy, with only SVF being used to treat OA. No serious adverse reactions, such as infection, acute pain, or cancer, were reported in any of these studies, indicating that SVF treatment for OA is safe. Most studies used adipose tissue from the abdomen, buttocks, and lateral thigh, with a volume (for one knee) ranging from 60 to 215 mL; the number of SVF cells varied from  $2 \times 10^6$  to  $3 \times 10^7$ ; and the final volume of SVF preparation used for intra-articular injection varied from 2.5 to 5 mL. Although it is difficult to maintain a unified standard for the degree of OA, the volume of adipose tissues, and the number and viability of SVF cells, existing studies have demonstrated a positive therapeutic effect, with VAS, WOMAC, ROM, MRI, KOOS, Lysholm, and other scores improving, the patient's pain decreasing, and inflammation symptoms decreasing. Simultaneously, joint function has been improved to a certain extent[43,44,47-55,60-62]. Figure 1 depicts the general steps of using SVF to treat OA in a current clinical setting.

It is worth noting that Garza found a significant difference in the final treatment effect of OA patients between the high-dose SVF ( $3 \times 10^7$ ) and low-dose SVF ( $1.5 \times 10^7$ ) groups. They pointed out that the median WOMAC score changes in the two groups after 6 mo of treatment were 83.9% and 51.5%, respectively. At the same time, the WOMAC scores of the high-dose and low-dose groups differed significantly from that of the control group, indicating that the degree of OA improvement is SVF dose-dependent[60].

Interestingly, Michalek used collagenase digestion and mechanical methods to obtain SVF. The results showed that the cell yield of the former was 3.4 times higher than that of the latter, and the cell activity was similar. The researchers then used the obtained SVF to randomly treat OA patients, and they discovered that the SVF obtained by the two extraction methods had the same therapeutic effect on OA, with no significant difference. As a result, it can be concluded that the SVF extraction method has little effect on OA treatment[47].

## THERAPEUTIC MECHANISMS OF SVF IN OA TREATMENT

When the body is damaged, signaling molecules are produced in the damaged area, activating the homing effect of stem cells, causing them to migrate to the damaged location and play a role in tissue repair[63]. However, cartilage tissues lack blood vessels. Even for bone marrow MSCs, it is difficult to migrate to the injury, so exogenous stem cell injection is needed. After SVF is injected into the joint cavity of patients, the ADSCs in the SVF can migrate to the damaged area through the interaction of various chemokine receptors (such as CXCR4, integrin, selectin, and vascular cell adhesion molecule-1) [64].

Although numerous studies have demonstrated that ADSCs can be induced to differentiate into chondrocytes *in vitro*, there is insufficient evidence to prove that ADSCs can differentiate into chondrocytes *in vivo* to repair damaged cartilage tissues during OA treatment. Existing evidence indicates that an important mechanism of the therapeutic effect of ADSCs is the nourishing effect of ADSCs; they can secrete growth factors and cytokines, such as transforming growth factor- $\beta$  (TGF- $\beta$ ),

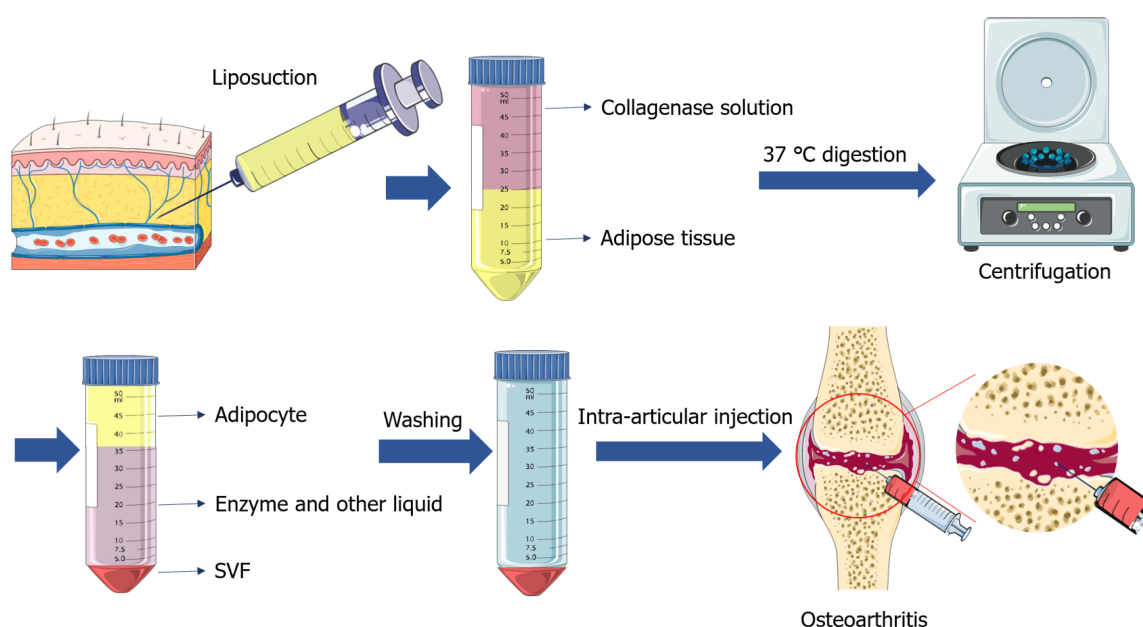


Table 2 Clinical researches on the treatment of osteoarthritis with stromal vascular fraction

Ref.	Treatment	Study type OA position/number	Patients	Follow-up time	Outcome assessments	Consequences
Pak <i>et al</i> [41,42] (2016, 2018)	SVF + HA + PRP	Case report Knee	3 patients: 1 male, age: 68; 2 females, age: 60 and 87	3.5 mo	FRI, MRI, ROM, VAS	Cartilage repaired showed by MRI; all scores improved
Fodor <i>et al</i> [43] (2016)	SVF	Pilot study Knee/8 OA	6 patients: 1 male, 5 females, mean age: 59	12 mo	ROM, WOMAC, VAS, TUG, MRI	All scores improved, no MRI evidence of cartilage regeneration
NCT02357485						
Yokota <i>et al</i> [44] (2017)	SVF	Case report Knee/26 OA	13 patients: 2 males, 11 females, mean age: 74.5	6 mo	VAS, JKOM, WOMAC	All scores improved
Nguyen <i>et al</i> [45] (2017)	AM vs AM + SVF + PRP	Comparative study Knee	30 patients (15 per group: 3 males, 12 females) mean age: 58	18 mo	VAS, Lysholm, WOMAC, MRI	All scores improved compared with AM group; AM + SVF + PRP group had obvious cartilage repair show by MRI
NCT02142842						
Michalek <i>et al</i> [46] (2017)	SVF	Case control multi-centric non-randomized study Knee and hip/1856 OA	1128 patients: 596 males, 532 females, median age: 62	17.2 mo	Modified KOOS/HOOS	KOOS/HOOS improved, most patients gradually improved, obesity and more severe OA healed slowly
Tantuway <i>et al</i> [47] (2017)	SVF	Case report Knee/201 OA	101 patients: 41 males, 60 females, age: 29-84	3-24 mo	KOOS	KOOS and joint function improved, pain relieved, patients could move normally
Russo <i>et al</i> [48, 49] (2017, 2018)	SVF	Retrospective study Diffuse degenerative keen	30 patients: 21 males, 9 females, median age: 43	12-36 mo	Lysholm, VAS, IKDC-subjective, KOOS	41%, 55%, 55%, 64% of the patients improved in the scores, respectively
Bright <i>et al</i> [50] (2018)	SVF	Case report Knee and hip	1 patient: female, age: 27	3 yr	WOMAC, HOOS	Symptoms of OA reduced, all scores improved, ankylosing spondylitis, depression, anxiety and fatigue improved
Barfod <i>et al</i> [51] (2019)	SVF	Prospective cohort study Knee	20 patients, mean age: 49	12 mo	KOOS	KOOS improved
NCT02697682						
Roato <i>et al</i> [52] (2019)	SVF	Case report Knee	20 patients: 9 males, 11 females, mean age: 59.6	18 mo	VAS, WOMAC	Pain relieved, scores improved
Hudetz <i>et al</i> [53] (2019)	SVF	Prospective, non-randomized and single center study Knee	20 patients: 15 males, 5 females	12 mo	VAS, WOMAC, KOOS	All scores improved, pain and symptoms relieved for up to a year
Berman <i>et al</i> [54] (2019)	SVF	Case report Knee	2586 patients	2-5 yr	Questionnaire (visual acuity pain scores, sustained improvement in function)	Over 80% of patients' pain relieved, joint function improved and maintain 1 yr; outcomes between male and female or between SVF alone and SVF + PRP showed no difference
NCT10953523						
Michalek <i>et al</i> [55] (2019)	SVF	Multicenter case-control study Knee and hip	29 patients: 9 males, 20 females, mean age: 83.3	36 mo	Modified KOOS/HOOS	Apart from 3 elderly patients died from aging, other patients' pain and weekly dosage of analgesics were reduced, KOOS/HOOS improved
Yokota <i>et al</i> [56] (2019)	ADSC vs SVF	Retrospective cohort study Knee/128 OA	ADSC: 42 patients; SVF: 38 patients	6 mo	VAS, KOOS	No major complications occurred, knee joint effusion was more likely to occur in SVF group than ADSC group (SVF 8%, ADSC 2%); VAS and KOOS improved in both groups
Mayoly <i>et al</i> [57] (2019)	SVF + PRP	Case report	3 patients: 1 male, 2 females, mean age: 62	12 mo	VAS, PRWE, DASH	All scores improved

NCT03164122		Wrist				
Hong <i>et al</i> [58] (2019)	SVF vs HA	Double-blind randomized self-controlled trial	16 patients (with bilateral symptomatic knee OA) one side: SVF, the other side: HA. 3 males, 13 females, mean age: 52	12 mo	VAS, WOMAC, ROM, MRI (MOCART, WORMS)	Significant improvement of VAS, WOMAC and ROM in SVF group, but no improvement in HA group; SVF group was superior to HA group in cartilage repair showed by MOCART and WORMS
Tran <i>et al</i> [59] (2019)	SVF + AM vs AM	Single-center, non-randomized, placebo-controlled study	33 patients, placebo group (AM): 3 males, 12 females, mean age: 58.2; SVF group (SVF + AM): 5 males, 13 females, mean age: 59	24 mo	VAS, WOMAC, Lysholm, OS	VAS, WOMAC of SVF group reduced significantly compared with placebo group, and maintained 24 mo; Lysholm, OS of SVF group improved
Garza <i>et al</i> [60] (2020)	SVF	Double-blinded prospective randomized controlled study	39 patients (randomly assigned to high-, low-dose SVF, or placebo at 1:1:1)	12 mo	WOMAC, MRI	Symptoms and pain relieved by SVF treatment for up to at least 12 mo; changes in WOMAC scores reached statistical significance in the high- and low-dose groups compared to the placebo group; the improvements were dose dependent
NCT02726945		Knee				
Lapiente <i>et al</i> [61] (2020)	SVF	Retrospective study	50 patients: 28 males, 22 females, age: 50-89	12 mo	Lequesne, WOMAC, VAS	All scores improved
Tsubosaka <i>et al</i> [62] (2020)	SVF	Case report	57 patients: 41 males, 16 females, mean age: 69.4	13.7 mo	ROM, WOMAC, VAS, KOOS, MRI	WOMAC, VAS and KOOS improved, while no significant difference in hip-knee-ankle angle, T2 mapping values of lateral femur and tibia improved significantly

HA: Hyaluronic acid; FRI: Functional rating index; MRI: Magnetic resonance imaging; VAS: Visual analogue score; ROM: Range of motion; WOMAC: Western Ontario and McMaster Universities Osteoarthritis Index; TUG: Timed up-and-go; JKOM: Japanese knee osteoarthritis measure; AM: Arthroscopic microfracture; OS: Outerbridge classification system; KOOS/HOOS: Knee/hip osteoarthritis outcome score; IKDC: International knee documentation committee-subjective; PRWE: Patient-rated wrist evaluation scores; DASH: Disabilities of the arm and shoulder; MOCART: Magnetic resonance observation of cartilage repair tissue score; BME: Bone marrow edema lesions; WORMS: Whole-organ magnetic resonance imaging score.



DOI: 10.4252/wjsc.v14.i10.744 Copyright ©The Author(s) 2022.

**Figure 1** Procedures for isolating stromal vascular fraction to treat osteoarthritis. SVF: Stromal vascular fraction.

bone morphogenetic proteins (BMP-2, BMP-4, and BMP-7), insulin-like growth factor 1 (IGF-1), and fibroblast growth factor-2 (FGF-2). As a result, ADSCs may promote cartilage formation, induce cell proliferation, differentiation, and migration and ultimately promote cartilage injury repair[65].

Furthermore, ADSCs may secrete NO, TNF- $\alpha$ , IL, and other cytokines, which play a role in regulating the body's immunity and anti-inflammatory response[66]. At the same time, ADSCs can inhibit chondrocyte apoptosis by expressing antiapoptotic proteins, thereby slowing the onset of OA[67].

Many researchers have used PRP in combination with stem cells to treat OA and have achieved satisfactory therapeutic effects. This is because PRP can release a variety of growth factors, such as platelet-derived growth factor, TGF, FGF, and various ILs. These growth factors can not only regulate the body's immune response but can also promote and enhance the repair function of stem cells. Therefore, PRP can stimulate the proliferation and differentiation of chondrocytes, regulate the synthesis of endogenous hyaluronic acid, and help to repair cartilage tissue damage[68].

SVF is a multicellular component that, in addition to ADSCs, also contains progenitor cells, pericytes, endothelial cells, fibroblasts, and various immune cells. These cells also aid in the promotion of cartilage repair by forming the microenvironment, secreting cytokines, and regulating immunity[56].

## DISCUSSION

Unfortunately, no complete cure exists for OA, and once a cartilage lesion occurs, it will gradually degenerate. As a result, the early diagnosis and treatment of OA are critical. Considering that osteoarthritis is a whole joint disease, OA should be treated with combined therapy. Through intraarticular injection therapy, treatment agents can directly reach the damaged site, which can not only allow drugs and especially stem cells to avoid being cleared by the body but also reduce the potential systemic effects of drugs[69]. Especially for traumatic arthritis, cartilage adipose stem cells provide a new avenue for the treatment of this type of arthritis through their powerful differentiation ability and paracrine and anti-inflammatory effects. Therefore, intraarticular injection therapy should be added to the combined treatment of OA. Increasing evidence shows that intraarticular injection of SVF is an effective treatment option for repairing articular cartilage damage, but there is a lack of clinical outcome data for long-term follow-up. Studies have indicated that the functional effect of cell therapy depends more on the quality of cytokines, chemokines and growth factors released by stem cells than on the number of stem cells. The stem cell activity of adipose-derived SVF was three times higher than that of bone marrow mesenchymal stem cells (BM-MSCs). At the same time, SVF does not require to be cultured *in vitro*, and its extraction and processing are also easier[70]. Therefore, AD-SVF has more advantages than BM-MSCs in the performance and ethical review of the treatment of osteoarthritis. Furthermore, the use of SVF to treat OA has certain individual differences, such as differences in extraction methods and equipment, which result in a variation in the number and quality of extracted cells. Simultaneously, the amount of fat acquired and the final cell yield of different patients are difficult to reconcile. The number of SVF cells used in the final treatment of OA varies by up to 10-fold in different studies. As a result, more detailed and comprehensive extraction standards and treatment guidelines for the use of SVF for OA treatment are needed.

The fact that SVF has a high safety profile in the treatment of OA is encouraging. Some researchers have used SVF in conjunction with other measures (such as the use of HA, microfracture, and PRP), and the results have been promising. As a result, in the future, a combination of multiple treatments, such as SVF combined with weight loss, exercise, and acupuncture to treat OA, may be considered, providing new treatment options for this disease. All of the patients who received SVF treatment had no serious adverse reactions, such as infection, acute pain, or cancer. Although patients occasionally experience minor reactions, such as joint effusion, swelling, pain congestion, and itching at the liposuction site, they can recover without intervention or improve with simple treatment. However, most clinical studies have certain limitations, such as a small number of clinical patients, a short follow-up period, and a lack of randomized controlled trials. As a result, in future studies, a more comprehensive and appropriate study design is needed. Recently, it has been concluded that clodronate can reduce pain and improve joint mobility by intraarticular injection for OA treatment. Combined with HA, clodronate can also relieve pain and reduce bone marrow lesions in early OA. In the future, it may be used in conjunction with SVF for better results[71].

## CONCLUSION

In conclusion, SVF is an effective treatment for repairing articular cartilage damage, especially for relieving pain and other symptoms and improving joint function in OA patients. At the same time, clinical treatment with SVF is very safe. Relevant mechanistic studies revealed the beneficial role of SVF and its paracrine molecules in the treatment of osteoarthritis, which can mediate intercellular communication and interact with the cellular microenvironment and a variety of cell types, thus triggering appropriate cellular responses, inhibiting inflammation, promoting cartilage repair and regeneration and restoring joint homeostasis to reduce pain. However, various factors can change the characteristics of SVF and its secretion, such as individual differences in donors and different preparation standards, which may limit its therapeutic effect. Therefore, a further in-depth research is

still needed to make stem cells a routine clinical treatment for diseases such as osteoarthritis.

## FOOTNOTES

**Author contributions:** Tang Q and Zhao XS contributed data collection and manuscript writing; Guo A, Cui RT, Song HL, Qi ZY, Pan Y, Yang Y contributed data analysis; Zhang FF, Jin L contributed study design and supervision; all authors have read and approve the final manuscript.

**Supported by** National Natural Science Foundation of China, No. 82070801, No. 82100858, No. 82073227; China Postdoctoral Science Foundation, No. 2020M671661; Jiangsu Province Science Foundation for Youths, No. BK20200569; and Jiangsu Province Research Founding for Postdoctoral, No. 1412000016.

**Conflict-of-interest statement:** All the authors report no relevant conflicts of interest for this article.

**Open-Access:** This article is an open-access article that was selected by an in-house editor and fully peer-reviewed by external reviewers. It is distributed in accordance with the Creative Commons Attribution NonCommercial (CC BY-NC 4.0) license, which permits others to distribute, remix, adapt, build upon this work non-commercially, and license their derivative works on different terms, provided the original work is properly cited and the use is non-commercial. See: <https://creativecommons.org/licenses/by-nc/4.0/>

**Country/Territory of origin:** China

**ORCID number:** Liang Jin 0000-0002-1954-4345.

**S-Editor:** Gong ZM

**L-Editor:** A

**P-Editor:** Gong ZM

## REFERENCES

- 1 Lambova SN, Müller-Ladner U. Osteoarthritis - Current Insights in Pathogenesis, Diagnosis and Treatment. *Curr Rheumatol Rev* 2018; **14**: 91-97 [PMID: 30003854 DOI: 10.2174/157339711402180706144757]
- 2 Georgiev T, Angelov AK. Modifiable risk factors in knee osteoarthritis: treatment implications. *Rheumatol Int* 2019; **39**: 1145-1157 [PMID: 30911813 DOI: 10.1007/s00296-019-04290-z]
- 3 Glyn-Jones S, Palmer AJ, Agricola R, Price AJ, Vincent TL, Weinans H, Carr AJ. Osteoarthritis. *Lancet* 2015; **386**: 376-387 [PMID: 25748615 DOI: 10.1016/S0140-6736(14)60802-3]
- 4 Safiri S, Kolahi AA, Smith E, Hill C, Bettampadi D, Mansournia MA, Hoy D, Ashrafi-Asgarabad A, Sepidarkish M, Almasi-Hashiani A, Collins G, Kaufman J, Qorbani M, Moradi-Lakeh M, Woolf AD, Guillemin F, March L, Cross M. Global, regional and national burden of osteoarthritis 1990-2017: a systematic analysis of the Global Burden of Disease Study 2017. *Ann Rheum Dis* 2020; **79**: 819-828 [PMID: 32398285 DOI: 10.1136/annrheumdis-2019-216515]
- 5 Wang T, He C. Pro-inflammatory cytokines: The link between obesity and osteoarthritis. *Cytokine Growth Factor Rev* 2018; **44**: 38-50 [PMID: 30340925 DOI: 10.1016/j.cytogfr.2018.10.002]
- 6 Kulkarni K, Karssiens T, Kumar V, Pandit H. Obesity and osteoarthritis. *Maturitas* 2016; **89**: 22-28 [PMID: 27180156 DOI: 10.1016/j.maturitas.2016.04.006]
- 7 Warner SC, Valdes AM. Genetic association studies in osteoarthritis: is it fairytale? *Curr Opin Rheumatol* 2017; **29**: 103-109 [PMID: 27755178 DOI: 10.1097/BOR.0000000000000352]
- 8 Suter LG, Smith SR, Katz JN, Englund M, Hunter DJ, Frobell R, Losina E. Projecting Lifetime Risk of Symptomatic Knee Osteoarthritis and Total Knee Replacement in Individuals Sustaining a Complete Anterior Cruciate Ligament Tear in Early Adulthood. *Arthritis Care Res (Hoboken)* 2017; **69**: 201-208 [PMID: 27214559 DOI: 10.1002/acr.22940]
- 9 Vaishya R, Vijay V, Lama P, Agarwal A. Does vitamin D deficiency influence the incidence and progression of knee osteoarthritis? *J Clin Orthop Trauma* 2019; **10**: 9-15 [PMID: 30705525 DOI: 10.1016/j.jcot.2018.05.012]
- 10 Alentorn-Geli E, Samuelsson K, Musahl V, Green CL, Bhandari M, Karlsson J. The Association of Recreational and Competitive Running With Hip and Knee Osteoarthritis: A Systematic Review and Meta-analysis. *J Orthop Sports Phys Ther* 2017; **47**: 373-390 [PMID: 28504066 DOI: 10.2519/jospt.2017.7137]
- 11 Nevitt MC, Zhang Y, Jawaideh MK, Neogi T, Curtis JR, Niu J, McCulloch CE, Segal NA, Felson DT. High systemic bone mineral density increases the risk of incident knee OA and joint space narrowing, but not radiographic progression of existing knee OA: the MOST study. *Ann Rheum Dis* 2010; **69**: 163-168 [PMID: 19147619 DOI: 10.1136/ard.2008.099531]
- 12 Marmor L. Lateral compartment arthroplasty of the knee. *Clin Orthop Relat Res* 1984; **115**: 115-121 [PMID: 6723132]
- 13 Sokolove J, Lepus CM. Role of inflammation in the pathogenesis of osteoarthritis: latest findings and interpretations. *Ther Adv Musculoskelet Dis* 2013; **5**: 77-94 [PMID: 23641259 DOI: 10.1177/1759720X12467868]
- 14 Rahmati M, Nalesso G, Mobasheri A, Mozafari M. Aging and osteoarthritis: Central role of the extracellular matrix. *Ageing Res Rev* 2017; **40**: 20-30 [PMID: 28774716 DOI: 10.1016/j.arr.2017.07.004]
- 15 Wojdasiewicz P, Poniatowski LA, Szukiewicz D. The role of inflammatory and anti-inflammatory cytokines in the pathogenesis of osteoarthritis. *Mediators Inflamm* 2014; **2014**: 561459 [PMID: 24876674 DOI: 10.1155/2014/561459]

- 16 Li G, Yin J, Gao J, Cheng TS, Pavlos NJ, Zhang C, Zheng MH. Subchondral bone in osteoarthritis: insight into risk factors and microstructural changes. *Arthritis Res Ther* 2013; **15**: 223 [PMID: [24321104](#) DOI: [10.1186/ar4405](#)]
- 17 Holzer LA, Kraiger M, Talakic E, Fritz GA, Avian A, Hofmeister A, Leithner A, Holzer G. Microstructural analysis of subchondral bone in knee osteoarthritis. *Osteoporos Int* 2020; **31**: 2037-2045 [PMID: [32472294](#) DOI: [10.1007/s00198-020-05461-6](#)]
- 18 Udomsinprasert W, Jinawath A, Teerawattanapong N, Honsawek S. Interleukin-34 overexpression mediated through tumor necrosis factor-alpha reflects severity of synovitis in knee osteoarthritis. *Sci Rep* 2020; **10**: 7987 [PMID: [32409720](#) DOI: [10.1038/s41598-020-64932-2](#)]
- 19 Roemer FW, Demehri S, Omoumi P, Link TM, Kijowski R, Saarakkala S, Crema MD, Guermazi A. State of the Art: Imaging of Osteoarthritis-Revisited 2020. *Radiology* 2020; **296**: 5-21 [PMID: [32427556](#) DOI: [10.1148/radiol.2020192498](#)]
- 20 Khatri C, Dickenson E, Ahmed I, Bretherton C, Ranaboldo T, Shaw C, Quarcoopome J, Plastow R, Downham C, Rasidovic D, Plant C, Barlow T. ARthroscopy in Knee OsteoArthritis (ARK-OA): a multicentre study assessing compliance to national guidelines. *Eur J Orthop Surg Traumatol* 2021; **31**: 1443-1449 [PMID: [33611640](#) DOI: [10.1007/s00590-021-02905-5](#)]
- 21 Demehri S, Guermazi A, Kwok CK. Diagnosis and Longitudinal Assessment of Osteoarthritis: Review of Available Imaging Techniques. *Rheum Dis Clin North Am* 2016; **42**: 607-620 [PMID: [27742017](#) DOI: [10.1016/j.rdc.2016.07.004](#)]
- 22 Hayashi D, Roemer FW, Guermazi A. Imaging for osteoarthritis. *Ann Phys Rehabil Med* 2016; **59**: 161-169 [PMID: [26797169](#) DOI: [10.1016/j.rehab.2015.12.003](#)]
- 23 Roemer FW, Kwok CK, Hayashi D, Felson DT, Guermazi A. The role of radiography and MRI for eligibility assessment in DMOAD trials of knee OA. *Nat Rev Rheumatol* 2018; **14**: 372-380 [PMID: [29752462](#) DOI: [10.1038/s41584-018-0010-z](#)]
- 24 Wakefield RJ, Balint PV, Szkudlarek M, Filippucci E, Backhaus M, D'Agostino MA, Sanchez EN, Iagnocco A, Schmidt WA, Bruyn GA, Kane D, O'Connor PJ, Manger B, Joshua F, Koski J, Grassi W, Lassere MN, Swen N, Kainberger F, Klauser A, Ostergaard M, Brown AK, Machold KP, Conaghan PG; OMERACT 7 Special Interest Group. Musculoskeletal ultrasound including definitions for ultrasonographic pathology. *J Rheumatol* 2005; **32**: 2485-2487 [PMID: [16331793](#)]
- 25 Katz JN, Brownlee SA, Jones MH. The role of arthroscopy in the management of knee osteoarthritis. *Best Pract Res Clin Rheumatol* 2014; **28**: 143-156 [PMID: [24792949](#) DOI: [10.1016/j.berh.2014.01.008](#)]
- 26 Saberi Hosnijeh F, Bierma-Zeinstra SM, Bay-Jensen AC. Osteoarthritis year in review 2018: biomarkers (biochemical markers). *Osteoarthritis Cartilage* 2019; **27**: 412-423 [PMID: [30552966](#) DOI: [10.1016/j.joca.2018.12.002](#)]
- 27 Lotz M, Martel-Pelletier J, Christiansen C, Brandi ML, Bruyère O, Chapurlat R, Collette J, Cooper C, Giacobelli G, Kanis JA, Karsdal MA, Kraus V, Lems WF, Meulenbelt I, Pelletier JP, Raynaud JP, Reiter-Niesert S, Rizzoli R, Sandell LJ, Van Spil WE, Reginster JY. Republished: Value of biomarkers in osteoarthritis: current status and perspectives. *Postgrad Med J* 2014; **90**: 171-178 [PMID: [24534711](#) DOI: [10.1136/postgradmedj-2013-203726rep](#)]
- 28 Bannuru RR, Osani MC, Vaysbrot EE, Arden NK, Bennell K, Bierma-Zeinstra SMA, Kraus VB, Lohmander LS, Abbott JH, Bhandari M, Blanco FJ, Espinosa R, Haugen IK, Lin J, Mandl LA, Moilanen E, Nakamura N, Snyder-Mackler L, Trojjan T, Underwood M, McAlindon TE. OARSI guidelines for the non-surgical management of knee, hip, and polyarticular osteoarthritis. *Osteoarthritis Cartilage* 2019; **27**: 1578-1589 [PMID: [31278997](#) DOI: [10.1016/j.joca.2019.06.011](#)]
- 29 Migliore A, Paoletta M, Moretti A, Liguori S, Iolascon G. The perspectives of intra-articular therapy in the management of osteoarthritis. *Expert Opin Drug Deliv* 2020; **17**: 1213-1226 [PMID: [32543240](#) DOI: [10.1080/17425247.2020.1783234](#)]
- 30 Belsey J, Yassen SK, Jobson S, Faulkner J, Wilson AJ. Return to Physical Activity After High Tibial Osteotomy or Unicompartmental Knee Arthroplasty: A Systematic Review and Pooling Data Analysis. *Am J Sports Med* 2021; **49**: 1372-1380 [PMID: [32960075](#) DOI: [10.1177/0363546520948861](#)]
- 31 Klag KA, Horton WA. Advances in treatment of achondroplasia and osteoarthritis. *Hum Mol Genet* 2016; **25**: R2-R8 [PMID: [26443596](#) DOI: [10.1093/hmg/ddv419](#)]
- 32 Shah FS, Wu X, Dietrich M, Rood J, Gimble JM. A non-enzymatic method for isolating human adipose tissue-derived stromal stem cells. *Cytotherapy* 2013; **15**: 979-985 [PMID: [23725689](#) DOI: [10.1016/j.jcyt.2013.04.001](#)]
- 33 Markarian CF, Frey GZ, Silveira MD, Chem EM, Milani AR, Ely PB, Horn AP, Nardi NB, Camassola M. Isolation of adipose-derived stem cells: a comparison among different methods. *Biotechnol Lett* 2014; **36**: 693-702 [PMID: [24322777](#) DOI: [10.1007/s10529-013-1425-x](#)]
- 34 Busser H, De Bruyn C, Urbain F, Najar M, Pieters K, Raicevic G, Meuleman N, Bron D, Lagneaux L. Isolation of adipose-derived stromal cells without enzymatic treatment: expansion, phenotypical, and functional characterization. *Stem Cells Dev* 2014; **23**: 2390-2400 [PMID: [24805167](#) DOI: [10.1089/scd.2014.0071](#)]
- 35 Zhao X, Guo J, Zhang F, Zhang J, Liu D, Hu W, Yin H, Jin L. Therapeutic application of adipose-derived stromal vascular fraction in diabetic foot. *Stem Cell Res Ther* 2020; **11**: 394 [PMID: [32928305](#) DOI: [10.1186/s13287-020-01825-1](#)]
- 36 Bourin P, Bunnell BA, Casteilla L, Dominici M, Katz AJ, March KL, Redl H, Rubin JP, Yoshimura K, Gimble JM. Stromal cells from the adipose tissue-derived stromal vascular fraction and culture expanded adipose tissue-derived stromal/stem cells: a joint statement of the International Federation for Adipose Therapeutics and Science (IFATS) and the International Society for Cellular Therapy (ISCT). *Cytotherapy* 2013; **15**: 641-648 [PMID: [23570660](#) DOI: [10.1016/j.jcyt.2013.02.006](#)]
- 37 Baer PC, Geiger H. Adipose-derived mesenchymal stromal/stem cells: tissue localization, characterization, and heterogeneity. *Stem Cells Int* 2012; **2012**: 812693 [PMID: [22577397](#) DOI: [10.1155/2012/812693](#)]
- 38 Miana VV, González EAP. Adipose tissue stem cells in regenerative medicine. *Ecancermedicalscience* 2018; **12**: 822 [PMID: [29662535](#) DOI: [10.3332/ecancer.2018.822](#)]
- 39 Aust L, Devlin B, Foster SJ, Halvorsen YD, Hicok K, du Laney T, Sen A, Willingmyre GD, Gimble JM. Yield of human adipose-derived adult stem cells from liposuction aspirates. *Cytotherapy* 2004; **6**: 7-14 [PMID: [14985162](#) DOI: [10.1080/14653240310004539](#)]
- 40 Strioga M, Viswanathan S, Darinskas A, Slaby O, Michalek J. Same or not the same? *Stem Cells Dev* 2012; **21**: 2724-2752 [PMID: [22468918](#) DOI: [10.1089/scd.2011.0722](#)]



- 41 **Pak J**, Lee JH, Park KS, Jeong BC, Lee SH. Regeneration of Cartilage in Human Knee Osteoarthritis with Autologous Adipose Tissue-Derived Stem Cells and Autologous Extracellular Matrix. *Biores Open Access* 2016; **5**: 192-200 [PMID: 27588219 DOI: 10.1089/biores.2016.0024]
- 42 **Pak J**, Lee JH, Pak NJ, Park KS, Jeon JH, Jeong BC, Lee SH. Clinical Protocol of Producing Adipose Tissue-Derived Stromal Vascular Fraction for Potential Cartilage Regeneration. *J Vis Exp* 2018 [PMID: 30320755 DOI: 10.3791/58363]
- 43 **Fodor PB**, Paulseth SG. Adipose Derived Stromal Cell (ADSC) Injections for Pain Management of Osteoarthritis in the Human Knee Joint. *Aesthet Surg J* 2016; **36**: 229-236 [PMID: 26238455 DOI: 10.1093/asj/sjv135]
- 44 **Yokota N**, Yamakawa M, Shirata T, Kimura T, Kaneshima H. Clinical results following intra-articular injection of adipose-derived stromal vascular fraction cells in patients with osteoarthritis of the knee. *Regen Ther* 2017; **6**: 108-112 [PMID: 30271845 DOI: 10.1016/j.reth.2017.04.002]
- 45 **Nguyen PD**, Tran TD, Nguyen HT, Vu HT, Le PT, Phan NL, Vu NB, Phan NK, Van Pham P. Comparative Clinical Observation of Arthroscopic Microfracture in the Presence and Absence of a Stromal Vascular Fraction Injection for Osteoarthritis. *Stem Cells Transl Med* 2017; **6**: 187-195 [PMID: 28170179 DOI: 10.5966/sctm.2016-0023]
- 46 **Michalek J**, Moster R, Lukac L, Proefrock K, Petrasovic M, Rybar J, Chaloupka A, Darinskas A, Michalek J, Kristek J, Travnik J, Jabandziev P, Cibulka M, Skopalik J, Kristkova Z, Dudasova Z. Stromal Vascular Fraction Cells of Adipose and Connective Tissue in People with Osteoarthritis: A Case Control Prospective Multi-Centric Non-Randomized Study. *Global Surg* 2017; **3**: 1-9 [DOI: 10.15761/GOS.1000163]
- 47 **Tantuway V**, Sharma AK, Mehta MH, Sharma R, Mantry P, Mehto P. Use of Autologous Adipose-derived Stromal Vascular Fraction Grafting in Treatment of Knee Osteoarthritis: A Safety and Efficacy Study. *J Med Res Prac* 2017; **6**: 119-127
- 48 **Russo A**, Condello V, Madonna V, Guerriero M, Zorzi C. Autologous and micro-fragmented adipose tissue for the treatment of diffuse degenerative knee osteoarthritis. *J Exp Orthop* 2017; **4**: 33 [PMID: 28975547 DOI: 10.1186/s40634-017-0108-2]
- 49 **Russo A**, Screpis D, Di Donato SL, Bonetti S, Piovano G, Zorzi C. Autologous micro-fragmented adipose tissue for the treatment of diffuse degenerative knee osteoarthritis: an update at 3 year follow-up. *J Exp Orthop* 2018; **5**: 52 [PMID: 30569417 DOI: 10.1186/s40634-018-0169-x]
- 50 **Bright B**, Bright R, Bright P, Limaye A. Ankylosing spondylitis, chronic fatigue and depression improved after stromal vascular fraction treatment for osteoarthritis: a case report. *J Med Case Rep* 2018; **12**: 238 [PMID: 30153860 DOI: 10.1186/s13256-018-1776-y]
- 51 **Barfod KW**, Blønd L. Treatment of osteoarthritis with autologous and microfragmented adipose tissue. *Dan Med J* 2019; **66** [PMID: 31571571]
- 52 **Roato I**, Belisario DC, Compagno M, Lena A, Bistolfi A, Maccari L, Mussano F, Genova T, Godio L, Perale G, Formica M, Cambieri I, Castagnoli C, Robba T, Felli L, Ferracini R. Concentrated adipose tissue infusion for the treatment of knee osteoarthritis: clinical and histological observations. *Int Orthop* 2019; **43**: 15-23 [PMID: 30311059 DOI: 10.1007/s00264-018-4192-4]
- 53 **Hudetz D**, Borić I, Rod E, Jeleč Ž, Kunovac B, Polašek O, Vrdoljak T, Plečko M, Skelin A, Polančec D, Zenić L, Primorac D. Early results of intra-articular micro-fragmented lipospiate treatment in patients with late stages knee osteoarthritis: a prospective study. *Croat Med J* 2019; **60**: 227-236 [PMID: 31187950]
- 54 **Berman M**, Lander E, Grogan T, O'Brien W, Braslow J, Dowell S, Berman S. Prospective Study of Autologous Adipose Derived Stromal Vascular Fraction Containing Stem Cells for the Treatment of Knee Osteoarthritis. *In J Stem Cell Res Ther* 2019; **6**: 064 [DOI: 10.23937/2469-570X/1410064]
- 55 **Michalek J**, Vrablikova A, Darinskas A, Lukac L, Prucha J, Skopalik J, Travnik J, Cibulka M, Dudasova Z. Stromal vascular fraction cell therapy for osteoarthritis in elderly: Multicenter case-control study. *J Clin Orthop Trauma* 2019; **10**: 76-80 [PMID: 30705536 DOI: 10.1016/j.jcot.2018.11.010]
- 56 **Yokota N**, Hattori M, Ohtsuru T, Otsuji M, Lyman S, Shimomura K, Nakamura N. Comparative Clinical Outcomes After Intra-articular Injection With Adipose-Derived Cultured Stem Cells or Noncultured Stromal Vascular Fraction for the Treatment of Knee Osteoarthritis. *Am J Sports Med* 2019; **47**: 2577-2583 [PMID: 31373830 DOI: 10.1177/0363546519864359]
- 57 **Mayoly A**, Iniesta A, Curvale C, Kachouh N, Jaloux C, Eraud J, Vogtensperger M, Veran J, Grimaud F, Jouve E, Casanova D, Sabatier F, Legré R, Magalon J. Development of Autologous Platelet-Rich Plasma Mixed-Microfat as an Advanced Therapy Medicinal Product for Intra-Articular Injection of Radio-Carpal Osteoarthritis: From Validation Data to Preliminary Clinical Results. *Int J Mol Sci* 2019; **20** [PMID: 30841510 DOI: 10.3390/ijms20051111]
- 58 **Hong Z**, Chen J, Zhang S, Zhao C, Bi M, Chen X, Bi Q. Intra-articular injection of autologous adipose-derived stromal vascular fractions for knee osteoarthritis: a double-blind randomized self-controlled trial. *Int Orthop* 2019; **43**: 1123-1134 [PMID: 30109404 DOI: 10.1007/s00264-018-4099-0]
- 59 **Tran TDX**, Wu CM, Dubey NK, Deng YH, Su CW, Pham TT, Thi Le PB, Sestili P, Deng WP. Time- and Kellgren-Lawrence Grade-Dependent Changes in Intra-Articularly Transplanted Stromal Vascular Fraction in Osteoarthritic Patients. *Cells* 2019; **8** [PMID: 30987218 DOI: 10.3390/cells8040308]
- 60 **Garza JR**, Campbell RE, Tjoumakaris FP, Freedman KB, Miller LS, Santa Maria D, Tucker BS. Clinical Efficacy of Intra-articular Mesenchymal Stromal Cells for the Treatment of Knee Osteoarthritis: A Double-Blinded Prospective Randomized Controlled Clinical Trial. *Am J Sports Med* 2020; **48**: 588-598 [PMID: 32109160 DOI: 10.1177/0363546519899923]
- 61 **Lapiente JP**, Dos-Anjos S, Blázquez-Martínez A. Intra-articular infiltration of adipose-derived stromal vascular fraction cells slows the clinical progression of moderate-severe knee osteoarthritis: hypothesis on the regulatory role of intra-articular adipose tissue. *J Orthop Surg Res* 2020; **15**: 137 [PMID: 32272946 DOI: 10.1186/s13018-020-01664-z]
- 62 **Tsubosaka M**, Matsumoto T, Sobajima S, Matsushita T, Iwaguro H, Kuroda R. The influence of adipose-derived stromal vascular fraction cells on the treatment of knee osteoarthritis. *BMC Musculoskelet Disord* 2020; **21**: 207 [PMID: 32252731 DOI: 10.1186/s12891-020-03231-3]
- 63 **Sohni A**, Verfaillie CM. Mesenchymal stem cells migration homing and tracking. *Stem Cells Int* 2013; **2013**: 130763 [PMID: 24194766 DOI: 10.1155/2013/130763]

- 64 **Docheva D**, Popov C, Mutschler W, Schieker M. Human mesenchymal stem cells in contact with their environment: surface characteristics and the integrin system. *J Cell Mol Med* 2007; **11**: 21-38 [PMID: [17367499](#) DOI: [10.1111/j.1582-4934.2007.00001.x](#)]
- 65 **Richardson SM**, Kalamegam G, Pushparaj PN, Matta C, Memic A, Khademhosseini A, Mobasheri R, Poletti FL, Hoyland JA, Mobasheri A. Mesenchymal stem cells in regenerative medicine: Focus on articular cartilage and intervertebral disc regeneration. *Methods* 2016; **99**: 69-80 [PMID: [26384579](#) DOI: [10.1016/j.ymeth.2015.09.015](#)]
- 66 **Yi T**, Song SU. Immunomodulatory properties of mesenchymal stem cells and their therapeutic applications. *Arch Pharm Res* 2012; **35**: 213-221 [PMID: [22370776](#) DOI: [10.1007/s12272-012-0202-z](#)]
- 67 **Shang J**, Liu H, Li J, Zhou Y. Roles of hypoxia during the chondrogenic differentiation of mesenchymal stem cells. *Curr Stem Cell Res Ther* 2014; **9**: 141-147 [PMID: [24372326](#) DOI: [10.2174/1574888x09666131230142459](#)]
- 68 **Nöth U**, Steinert AF, Tuan RS. Technology insight: adult mesenchymal stem cells for osteoarthritis therapy. *Nat Clin Pract Rheumatol* 2008; **4**: 371-380 [PMID: [18477997](#) DOI: [10.1038/ncprheum0816](#)]
- 69 **Georgiev T**. Multimodal approach to intraarticular drug delivery in knee osteoarthritis. *Rheumatol Int* 2020; **40**: 1763-1769 [PMID: [32803403](#) DOI: [10.1007/s00296-020-04681-7](#)]
- 70 **Jeyaraman M**, Muthu S, Ganie PA. Does the Source of Mesenchymal Stem Cell Have an Effect in the Management of Osteoarthritis of the Knee? *Cartilage* 2021; **13**: AAAA1532-1547 [PMID: [32840122](#) DOI: [10.1177/1947603520951623](#)]
- 71 **Moretti A**, Paoletta M, Liguori S, Ilardi W, Snichelotto F, Toro G, Gimigliano F, Iolascon G. The Rationale for the Intra-Articular Administration of Clodronate in Osteoarthritis. *Int J Mol Sci* 2021; **22** [PMID: [33799992](#) DOI: [10.3390/ijms22052693](#)]



Published by **Baishideng Publishing Group Inc**  
7041 Koll Center Parkway, Suite 160, Pleasanton, CA 94566, USA

**Telephone:** +1-925-3991568

**E-mail:** [bpgoffice@wjgnet.com](mailto:bpgoffice@wjgnet.com)

**Help Desk:** <https://www.f6publishing.com/helpdesk>

<https://www.wjgnet.com>

